



PRESENTING CLINICAL SIGNS

History: Grade 2-3/6 left apical systolic murmur.

DATE

12/9/21

ECHOCARDIOGRAPHIC FINDINGS

2D, M-mode, and Doppler study.

PERFORMED BY:

Dr. Nigel Gumley

Left atrial size is normal. The mitral valve appears normal. Left ventricular dimensions are normal, as is left ventricular systolic function. The aorta and aortic appear normal, though there is mildly increased flow velocity in the ascending aorta. Right atrial and right ventricular dimensions are normal. The tricuspid valve is normal. The pulmonary artery and pulmonic valve are normal. No heartworms are visualized. No pericardial effusion or cardiac masses are seen.

INTERPRETED BY

Keith Blass, DVM,
MS, DACVIM
(Cardiology)

ECG during echo: Sinus arrhythmia

PATIENT

Blanca Nadeau

LA - 38.6 mm
LVIDd - 40.3 mm
LVIDs - 25.7 mm
FS - 36%
RA - 21.7 mm
LVOT - 2.16 m/s
RVOT - 1.40 m/s

SPECIES

Canine

ASSESSMENT/RECOMMENDATIONS

Normal echocardiogram

BREED

American Bulldog

This examination demonstrates no evidence of structural heart disease. Blanca's murmur appears to be due to the presence of mildly increased flow velocity in her aorta, which is a common reason for a functional/innocent murmur to develop in dogs.

No therapy is recommended based on this exam.

SEX

A recheck echocardiogram is recommended if the characteristics of Blanca's murmur change, or if other new physical exam and/or clinical abnormalities suggestive of cardiac dysfunction develop.

FS

AGE

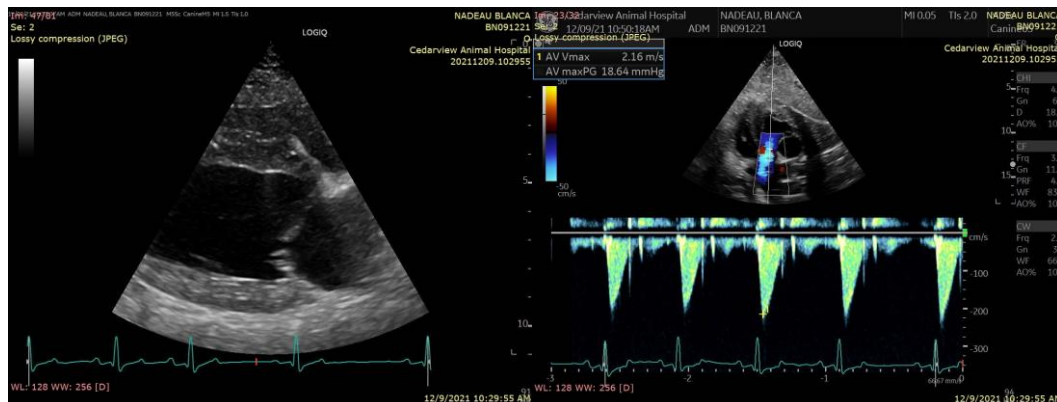
7 y

WEIGHT

29.3 kg

HOSPITAL NAME

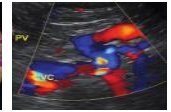
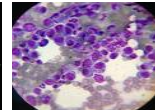
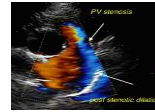
Cedarview AH



REFERRING VET

Dr. Gumley

The information and recommendations provided are based on the images presented by the



referring veterinarian. No evaluation can be communicated regarding pathology that was not visible in the image/video clips provided.

DATE

12/9/21

Thank you for this referral. If the clinical or image interpretation does not parallel your findings or if I can be of any further assistance please contact me.

PERFORMED BY: Keith Blass, DVM, MS, DACVIM (Cardiology)

KeithBlass@gmail.com
631-804-5754

Dr. Nigel Gumley

INTERPRETED BY

Keith Blass, DVM,
MS, DACVIM
(Cardiology)

PATIENT

Blanca Nadeau

SPECIES

Canine

BREED

American Bulldog

SEX

FS

AGE

7 y

WEIGHT

29.3 kg

HOSPITAL NAME

Cedarview AH

REFERRING VET

Dr. Gumley